

# Regional Veterinary Laboratories Report

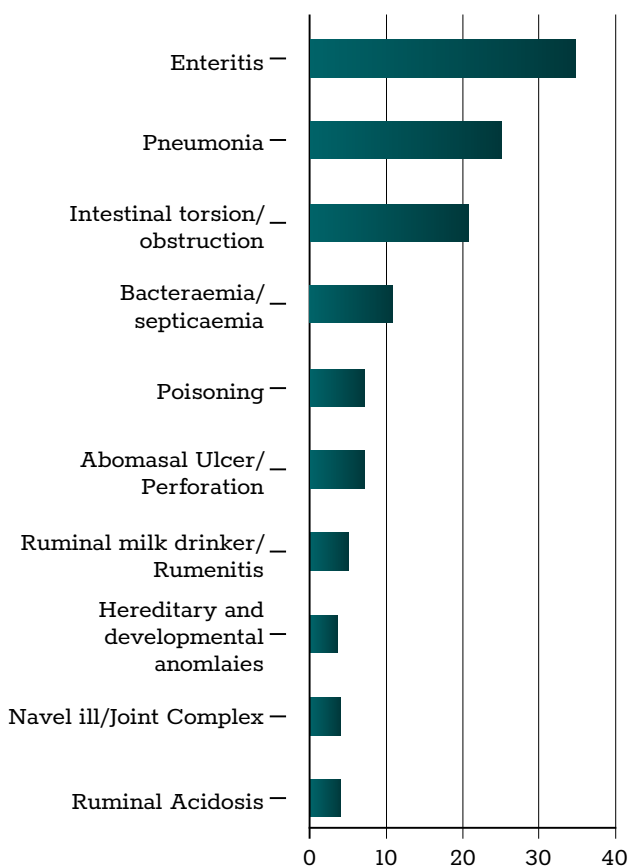
April 2022

Regional Veterinary Laboratories (RVLs) carried out necropsy examinations on 539 carcasses and 91 fetuses during May 2019. Additionally, 1,635 diagnostic samples were tested to assist private veterinary practitioners with the diagnosis and control of disease in food-producing animals. This report describes a selection of cases investigated by the Department of Agriculture, Food and the Marine's (DAFM) veterinary laboratories in April 2022.

The objective of this report is to provide feedback to veterinary practitioners on the pattern of disease syndromes at this time of the year by describing common and highlighting unusual cases. Moreover, we aim to assist with future diagnoses, encourage thorough investigations of clinical cases, highlight available laboratory diagnostic tools and provide a better context for practitioners when interpreting laboratory reports.

## CATTLE

Enteritis and pneumonia were the most common diagnoses from necropsies in cattle in the RVLs during April 2022.



**Table 1: The most common diagnoses in cattle submitted for necropsy in April 2022.**

## GASTROINTESTINAL TRACT

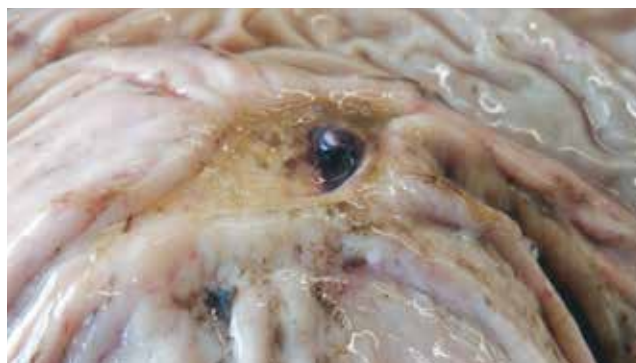### Enteritis

Enteritis was the most common diagnosis in cattle in the RVLs during April 2022. A typical example of such cases was examined by Limerick RVL. A ten-day-old Hereford-cross calf from a 30-cow dairy herd had been treated for diarrhoea but had deteriorated and died. Two other deaths were recorded. Necropsy disclosed heavy faecal soiling of the perineum,

enteritis and pulmonary congestion. *Cryptosporidium parvum* was detected in the intestinal contents.

### Abomasal ulceration

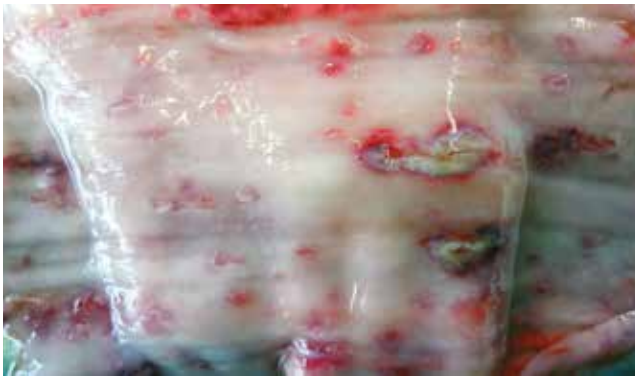A six-week-old calf with respiratory signs in the two days prior to death was submitted to Sligo RVL. On necropsy, the carcass was anaemic, severely dehydrated and the rumen appeared empty. There was multifocal haemorrhagic abomasal ulceration. There was concurrent moderate coccidiosis. The abomasal ulceration and the associated blood loss were the most likely cause of death. Anaemia can lead to dyspnoea due to hypoxia, which be mistaken as pneumonic signs. Many conditions are associated with the development of abomasal ulcers, and their pathogenesis has not been fully elucidated. Often, they are associated with concurrent disease and, in this case, there was concurrent coccidiosis. A three-year-old cow with a history of anaemia and reduced milk yield was submitted to Kilkenny RVL. On examination, the abomasum contained a black watery liquid. There was moderate abomasal fold oedema. There was one moderately deep ulcer with an exposed blood vessel. The intestinal contents were dark brown to black in colour, characteristic of digested blood. A diagnosis was made of abomasal ulceration with haemorrhage from the exposed vessel.



**Figure 1: An abomasal ulcer with an exposed blood vessel. Photo: Aideen Kennedy.**

A five-month-old weanling with respiratory signs was submitted to Kilkenny RVL having failed to respond to treatment with non-steroidal anti-inflammatory drugs

(NSAIDs) and antibiotics. Six other animals were affected. The weanling was severely dehydrated. There was multifocal ulceration on the mucosa of the oesophagus; some foci were hyperaemic, others had exudate in the centre. There was cranioventral consolidation affecting approximately 40 per cent of the lungs. There was marked multifocal abomasal ulceration and haemorrhages, the ulcers were of moderate depth. There was oedema in the abomasum wall with dark haemorrhages along the folds. *Histophilus somni* polymerase chain reaction (PCR) positive results were obtained on the lung and *Escherichia coli* was cultured from multiple organs suggesting a bacteraemia. Parapox PCR positive results were also obtained on a swab of oesophageal lesions.



**Figure 2: Oesophageal ulcers from which parapox virus was detected. Photo: Aideen Kennedy.**

On histology, there was severe, subacute, fibrino-suppurative bronchopneumonia and pleuritis. In the oesophagus, there was observed multifocal-to-coalescing areas of hyperplasia, ballooning degeneration and pustule formation with multifocal areas of ulceration, with a moderate infiltration of mainly macrophages and lymphocytes into the submucosa. Multiple cells contained intra-cytoplasmic eosinophilic inclusions. There was a severe multifocal-to-coalescing fibrino-suppurative necrotising abomasitis with vasculitis and thrombosis formation. There was also a severe necrotising enteritis. Although culture results were negative, *Salmonella* sp. infection cannot be excluded based on findings, and submission of blood and faecal samples from cohorts were recommended.



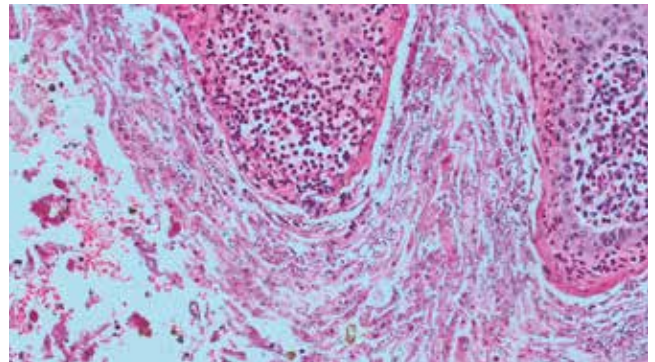
**Figure 3: Abomasal haemorrhages and ulceration. Photo: Aideen Kennedy.**

### Intestinal torsion/volvulus

A two-month-old Friesian heifer calf was submitted for necropsy to Limerick RVL after being found dead in its pen. Necropsy disclosed an intestinal volvulus ('bloody guts') associated with a mesenteric root torsion. Testing of a sample of the haemorrhagic intestinal contents was negative for *Clostridium perfringens* and its toxins. A diagnosis of intestinal volvulus was made.

### Ruminal milk drinking

A five-week-old calf was submitted to Kilkenny RVL. The calf was treated for bloat and recovered, subsequently became inappetent, and died despite treatment. In the abdominal cavity, there was peritonitis with strands of fibrin covering the serosal surface of a bloated abomasum. On the mucosal surface of the abomasum, there was multifocal haemorrhages and a moderate to deep ulcer near the pylorus. The rumen content was 'porridge-like' and contained milk (indicating that the calf was a 'ruminal drinker'). A very acidic pH of <4 was recorded. *E. coli* was detected on culture and bovine corona virus (BoCo) PCR results were positive. Peritonitis was diagnosed, likely associated with the abomasal ulcers. Subsequent history indicated that milk was being fed by stomach tube.



**Figure 4: Mycotic and bacterial rumenitis in a rumen milk drinker. Photo: Maresa Sheehan.**

### Rumen milk drinking

Multiple calves present every year with ruminal milk drinking to the RVLs. This is seen in many calves with other disease processes such as enteritis or with omphalophlebitis. Occasionally, a fungal infection is established in the rumen of these calves. Some of the proposed causes of rumen milk feeding are listed below. Stomach tubing calves with milk, other than their colostrum feed, is not recommended as the milk will tend to directly enter the forestomachs and can provide an environment for bacterial and fungal growth. *Candida albicans* and similar yeast structures are commonly seen in the rumen of a calf with milk in its rumen.

Main causes of Oesophageal Groove Dysfunction are:

- Neonatal diarrhoea, pain, phlebitis of the jugular vein;
- Inadequate feeding techniques – irregular feeding times, low-quality milk replacer, cold temperature of the milk, drinking from an open bucket;

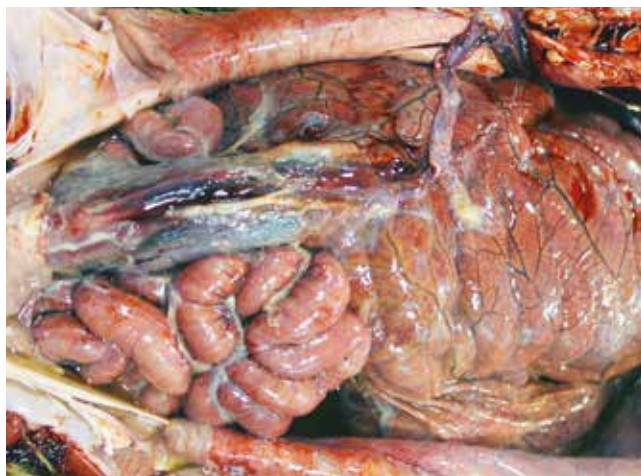- Forced feeding – discomfort caused by the passage of the feeding tube inhibits the groove closure reflex;
- Stress factors, e.g., long-distance transportation.

Stomach tubing of milk is not recommended as the effects of ruminal drinking can include:

- Inflammation of the rumen and reticulum mucosa, this can cause continued failure of groove closure, making the situation worse;
- Impaired ruminal motility;
- Atrophy of the intestinal villi, causing impaired absorption of nutrients;
- Lactic acidosis;
- Immunosuppression.

### Peritonitis

Athlone RVL examined a full-term perinatal calf that lived for 12 hours. The calving was unassisted, and the calf had suckled the cow. The calf was found recumbent a few hours later and died soon after. On gross post-mortem, there was a diffuse, fibrinous peritonitis with fibrin on the liver surface and between loops of intestines. There were echymotic haemorrhages on the spleen. The umbilicus was oedematous and haemorrhagic, and the abomasum and rumen contained mucus, but no evidence of milk or colostrum. A zinc sulphate turbidity test (ZST) score of five units indicated failure of passive transfer. *Mannheimia haemolytica* was isolated from the liver.



**Photo 5: Fibrinous peritonitis with fibrin between loops of intestines. Photo: Denise Murphy.**

### Hepatic lipidosis

Athlone RVL examined a ten-year-old Friesian cow that had been presented clinically to a veterinarian due to hypocalcaemia ('milk fever') or downer cow. According to the history received from the private veterinary practitioner (PVP), she had not been fed supplementary dry cow minerals prior to calving, and she initially responded to calcium treatment but became recumbent again the next day. Her temperature was normal, her eye was slightly sunken, and she was mildly constipated. There was no evidence of mastitis, her respiratory

rate was normal, and she had a red uterine discharge. She was given more calcium and magnesium, propylene glycol and oral fluids and was treated with antibiotics. She deteriorated that evening and was given intravenous hypertonic fluids, but she continued to deteriorate and was euthanised the next day. On gross post-mortem examination, the body condition was fat, bodyweight 688kg, and there were large amounts of visceral carcass fat. There was subcutaneous oedema over the right flank and ribcage due to recumbency. The liver had an orange/brown hue and was soft and greasy. There was a small amount of bloody fluid with some flocculent material in the uterus which was not involuted. There was right-sided pulmonary congestion and oedema and large volumes of fluids in rumen, reticulum and abomasum and soft intestinal contents. The kidneys and mammary glands were unremarkable. Beta hydroxybutyrate (BHB) concentration in aqueous humour was 2.3mmol/L which is elevated and highly suggestive of fatty liver disease/ketosis. The magnesium and calcium concentrations were within normal ranges. A conclusion of fatty liver disease and metritis in an over-conditioned older freshly-calved dairy cow was reached.

### RESPIRATORY TRACT

#### Pneumonia

A one-week-old purebred Aberdeen Angus calf was submitted to Limerick RVL with a history of signs of hyperventilation and depression for one day before death. Bronchopneumonia with abscessation of the cranial and middle lung lobes was detected at necropsy. Fibrin tags were observed in the peritoneal cavity. Hepatomegaly and haemorrhagic intestinal contents were found. Culture of the lungs yielded a mixed bacterial growth. Antibiotic treatment may have affected the culture results. Bacterial pneumonia was suspected, and histopathology supported this diagnosis.

### URINARY/REPRODUCTIVE TRACT

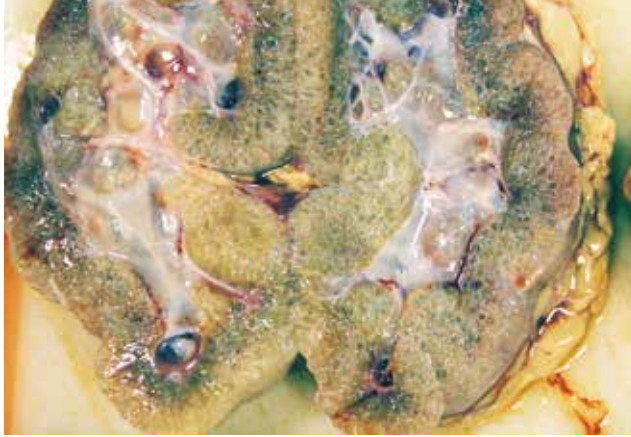#### Omphalophlebitis

A one-week-old calf with a history of a swollen umbilical and suspected cardiac signs was submitted to Sligo RVL. On post-mortem examination, there was a severe purulent omphalophlebitis extending up to the liver. The lungs were 50 per cent atelectic. *E. coli* was isolated from several organs. Omphalophlebitis and likely *E. coli* septicaemia were diagnosed as the cause of death. The partially inflated lungs were likely to have caused some postnatal weakness. A review of neonatal hygiene was recommended.

#### Renal dysplasia

Athlone RVL examined a five-day-old Charolais calf that had been very slow to suckle and had been tube-fed when born. The calf had been let outdoors and was found with slight dyspnoea the following morning, was treated by the veterinary surgeon, but died soon after. On gross post-mortem examination, the mucous membranes were pale. Bilaterally, the kidneys were pale and there were multiple small 1mm cysts diffusely throughout cortices and medulla. There was marked diffuse bilateral pulmonary congestion and oedema,

and the liver was enlarged. Urea levels in vitreous humour were very elevated at 45mmol/L (typically <7.3mmol/L) and are consistent with significant renal disease. Histopathology of the kidney showed asynchronous maturation, interstitial fibrosis, with foetal glomeruli, immature tubules, primitive mesenchyme, persistent metanephric ducts, and mild lymphoplasmacytic nephritis consistent with renal dysplasia.

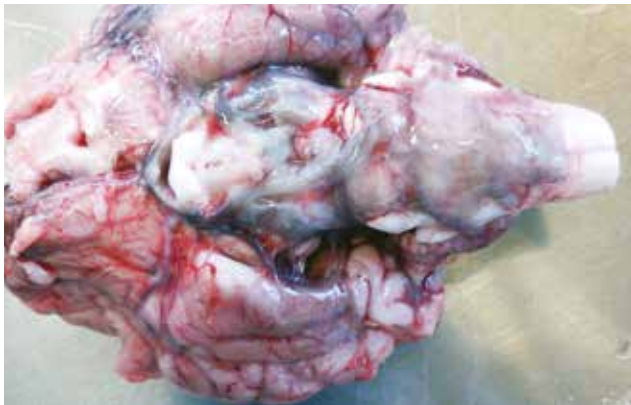

**Figure 6: Renal dysplasia with cysts diffusely throughout cortices and medulla. Photo: Denise Murphy.**

## NERVOUS SYSTEM

### Meningitis

A ten-day old calf with neurological signs was submitted to Kilkenny RVL. The calf was moderately dehydrated. The meninges appeared cloudy; this was more pronounced on gross inspection of the ventral aspect of the brainstem. The lungs were congested. There was milk in the rumen (rumen drinker). The synovial fluid was excessively turbid in a number of joints indicating a possible concurrent arthritis/polyserositis. On histopathology, there was a marked suppurative meningitis. In addition, there was an interstitial pneumonia with multifocal bacterial colonies visible. *E. coli* was cultured from multiple organs including a swab of the brain. A ZST score of four was obtained indicating failure of passive transfer. A review of colostrum management at calving was recommended.

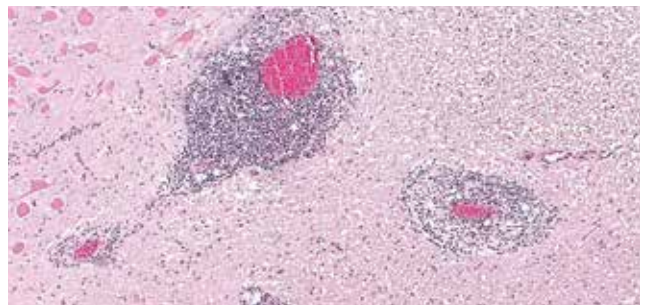


**Figure 7: Meninges with a cloudy appearance over the ventral brainstem in a calf with meningitis. Photo: Aideen Kennedy.**

The carcase of a recently euthanised yearling bullock was submitted to Sligo RVL for post-mortem examination. The animal had been bought three weeks prior in a mart and noticed some days previously as being dull, slow, and ataxic especially affecting the hindlimbs. It soon deteriorated to recumbency and had to be euthanised. There were three similar cases in the group. On post-mortem examination, there were multifocal subcutaneous and muscular haemorrhages on the carcase. There was fibrinous pericarditis. The meninges were congested and cloudy. The lungs presented with interlobular oedema and were heavy and wet. On histopathology, there was thrombosing meningoencephalitis. An infection with *Anaplasma phagocytophylum*, as well as bovine respiratory syncytial virus (BRSV), was detected by PCR. The cause of death was most likely meningitis of bacterial origin, with the most important differential diagnosis being an infection with *H. somni*. The presence of *A. phagocytophylum*, the causative agent of tick-borne fever (TBF) is considered significant in this case as it can cause profound immunosuppression. The significance of the RSV infection remained unclear but is assumed to have contributed as a co-infection that may have exacerbated signs in this animal. Control of ticks and further monitoring of herd for TBF was advised. TBF may only be present in a small subpopulation of ticks and is often localised to a particular area within a farm. Bought-in stock is most susceptible as immunity to TBF is effective and persistent in most home-reared animals.

### Listeriosis

A four-year-old Friesian cow was submitted to Limerick RVL with a history of neurological signs. A number of animals had been affected, and a batch of silage on the farm had been noted to be of poor quality. Necropsy disclosed severe pulmonary congestion/haemorrhage and interlobular emphysema. Spleen, liver and kidneys were congested. The intestinal mucosa was inflamed, and the small and large intestinal contents were fluid. The abomasal mucosa was inflamed and thickened. There was froth in the trachea. The brain was grossly unremarkable. Histopathology of the brainstem detected microabscessation and prominent perivascular lymphatic cuffing, signs associated with encephalitis due to *Listeria* sp., most commonly *Listeria monocytogenes*. A diagnosis of encephalitis due to *Listeria* sp. was made.



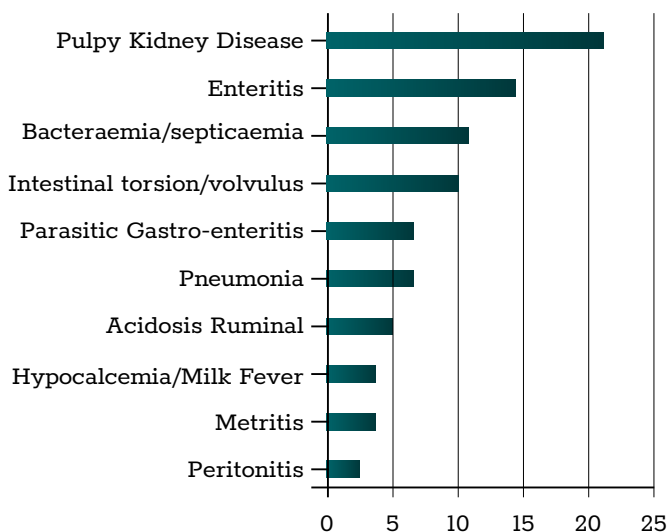
**Figure 8: Prominent perivascular lymphocytic cuffing together with microabscessation are signs associated with encephalitis due to *Listeria* sp. Photo: Ian Hogan.**

**MISCELLANEOUS**

An eight-day-old Limousin calf was submitted to Limerick RVL with a history of respiratory distress. It had collapsed with some nervous signs before death. Necropsy disclosed diffuse pulmonary congestion with froth in the trachea, hepatomegaly and splenomegaly. There was a mottled appearance to both kidneys with subcapsular haemorrhages. The gross findings were suggestive of bacteraemia/septicaemia, as were findings from histopathology. *Salmonella enterica* serotype Dublin was isolated from the liver and lung. Salmonellosis is a potential zoonosis and staff working with these animals should be advised of the importance of hygiene measures such as disinfection of work clothes and handwashing. Control of spread of *Salmonella* infection in cattle is by way of hygienic measures such as isolation of sick animals, and disinfection of contaminated fomites and houses. Vaccines are also available. Septicaemia associated with *Salmonella* Dublin infection was diagnosed.

**SHEEP**

Clostridial enterotoxaemia ('pulpy kidney disease') and enteritis were the most common diagnoses from necropsy in sheep in the RVLs during April 2022.



**Table 2: The most common diagnoses in sheep submitted for necropsy in April 2022.**

**GASTROINTESTINAL TRACT**

**Clostridial enterotoxaemia/pulpy kidney**

Three lambs were submitted to Limerick RVL with a history of sudden death. Necropsy of all three disclosed liquid intestinal contents, fluid in the abomasal cavity. Stomach content and mucosa were grossly normal. Fluid was observed in the pericardial sac of one lamb and a serous clot was found in the pericardial sac of another; this is a finding associated with clostridial enterotoxaemia. Random or diffuse congestion were seen in the lungs of two lambs. The kidneys were soft and friable in all three. *C. perfringens* and its epsilon toxin were detected in the intestinal contents of all three lambs. The relatively labile alpha toxin was also detected in one lamb. Clostridial enterotoxaemia or 'pulpy kidney' was diagnosed

in the lamb that tested positive for alpha and epsilon toxins, confirming the presence of *C. perfringens* Type D. It was considered that the other two lambs likely also died due to this condition.

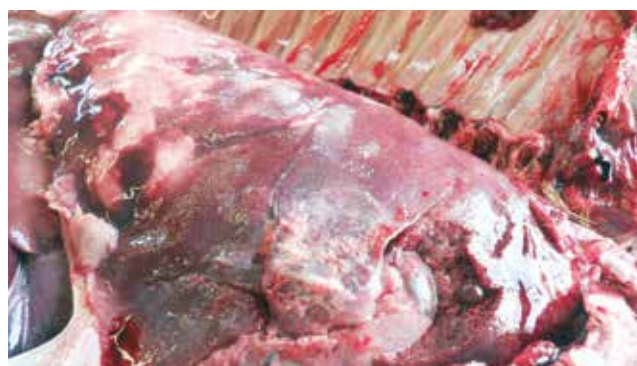**Ruminal acidosis**

Athlone RVL examined a four-week-old lamb with a history of having been found dull and lying against the fence; the lamb fell over when moved by the flock owner. He died later without having received any treatment. It was the fifth similar loss. On gross post-mortem examination, there was a severe, diffuse, bilateral, fibrinous pleurisy and pneumonia and a diffuse fibrinous peritonitis with fibrin on the liver surface and the serosa of the gastro-intestinal tract (GIT). There was a lot of grain in the rumen contents and there was no milk in the abomasum and colonic contents and faeces were soft. The umbilicus and joints were unremarkable. *E. coli* was isolated from several organs, and a moderate coccidial oocyst count was detected in a faecal sample. The rumen pH was 5.2, values <5.5 are suggestive of ruminal acidosis. A conclusion of peritonitis and pleuropneumonia was reached and a review of hygiene practices around lambing and colostrum intake was made. A review of the level of concentrate feeding was also advised.

**RESPIRATORY TRACT**

**Pneumonia**

A six-week-old lamb presented to Kilkenny RVL with a history of sudden death. There was a severe pneumonia affecting approximately 50 per cent of the lungs with marked cranioventral consolidation and abscessation. There were semi-solid contents in the large intestines and solid contents in the rectum. There were scarce contents in the small intestines. *M. haemolytica* was isolated from the lungs, the role of this bacteria in respiratory disease in sheep is well established. There were 1,000 strongyle eggs per gram (EPG) and 400 nematodirus EPG detected in the intestinal contents. Concurrent diseases such as parasitic gastroenteritis may increase susceptibility of animals to many disease processes.



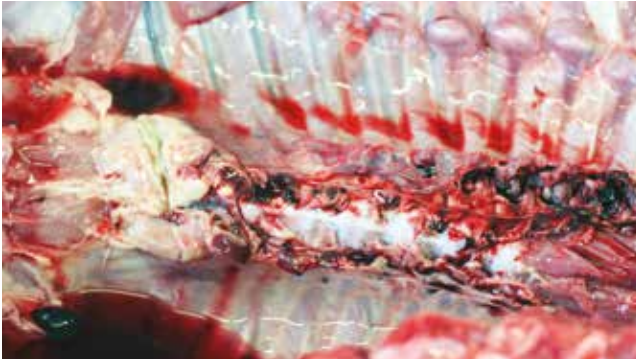
**Figure 9: Pneumonia in a lamb with marked cranioventral consolidation and abscessation. Photo: Maresa Sheehan.**

**MUSCULO-SKELETAL**

**Spinal abscess**

A six-week-old lamb with hindlimb paraplegia was submitted

to Sligo RVL. On post-mortem examination, there was a locally extensive spinal abscess in the cranial thoracic spine. Moreover, there were multifocal costal fractures. *E. coli* was cultured from the abscess material. The cause of the fracture could not be determined but is a common finding after hard lambings or calvings. The source of the abscess was not determined but is likely to have occurred following bacteraemia.



**Figure 10: Thoracic spinal abscess in a lamb; pus may be observed from an incision into the abscess (left). Photo: Colm Ó Muireagáin.**

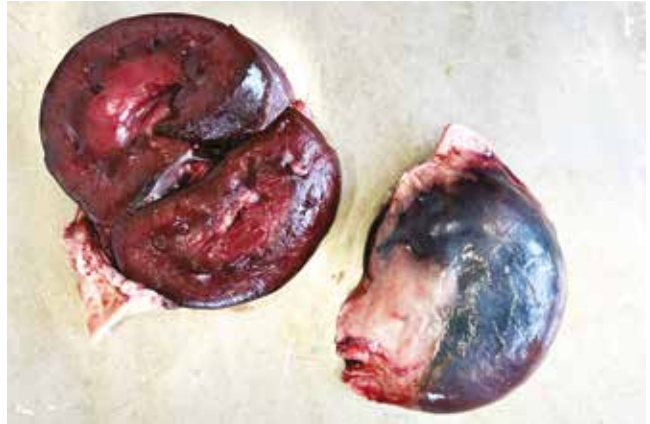#### **Clostridial cellulitis**

Sligo RVL examined a one-year-old hogget which had been described as not being able to stand just before death. It was the third death in the management group within a short time frame. On post-mortem examination, there was an area of cellulitis present on the right side of the dorsal costal arch involving subcutaneous tissue and muscle. It was approximately 15cm in diameter. There were multifocal haemorrhages present on the pleura. The lungs were wet and oedematous. *Clostridium novyi* was identified by fluorescent antibody technique (FAT) in the lesion. Toxaemia subsequent to *C. novyi* infection was diagnosed as the most likely cause of death. The location of cellulitis was considered unusual. History of three further sheep affected, as well as location of the lesion, made an injection site infection due to a contaminated hypodermic needle a likely cause.

#### **POISONINGS**

##### **Copper poisoning**

A two-year-old Texel ewe which had been described as dull, polydipsic and tachypnoeic was submitted to Sligo RVL. The farmer reported two similar cases in the previous year. On post-mortem examination, there was diffuse icterus. The liver appeared orange. Ruminal and intestinal contents were liquid. There were multifocal haemorrhages on the musculature and in the subcutaneous tissue. The kidneys were bilaterally dark. The bladder was empty. On histopathology of the kidneys, there were tubular haemoglobin casts. Copper concentrations in samples of both kidney and liver were within the toxic range. Copper poisoning was diagnosed as the cause of death. Texel sheep are particularly susceptible to copper poisoning and clinical signs may occur sometime after supplementation has occurred due to temporary storage in the liver.



**Figure 11: Dark kidneys from a ewe with copper poisoning. Photo: Shane McGettrick.**

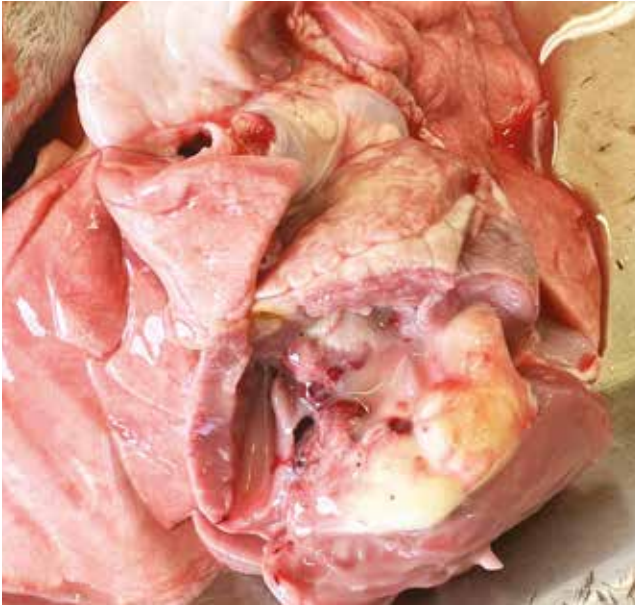#### **MISCELLANEOUS**

##### **Haemolytic anaemia**



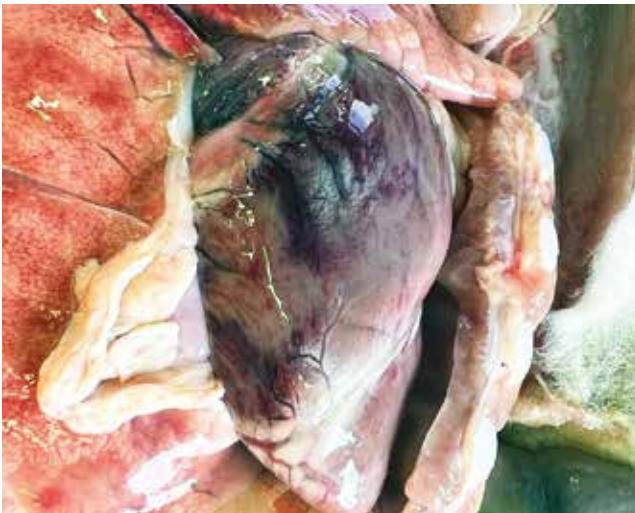**Figure 12: Pale and anaemic carcass of a lamb with haemolytic anaemia. Photo: Shane McGettrick.**

Sligo RVL diagnosed a small number of cases of immune-mediated haemolytic anaemia in lambs which was most likely caused by supplementary feeding of bovine colostrum. In one case, two two-week-old lambs were submitted from the same holding which also reported several more similar deaths. The lambs were described as developing progressive weakness over a seven-day period from birth. They were weak and slow to get up and appeared to be exhausted, and went into recumbency in any slightly stressful situation. Veterinary assistance was sought, and the blood was noted as pink to brown in colour and their body temperatures were below normal. There was no improvement following iron and antimicrobial injections.



**Figure 13: White intracardial clot in a lamb with haemolytic anaemia. Photo: Shane McGettrick.**

On post-mortem of both lambs, similar lesions were observed. Both carcasses appeared pale and anaemic. There were pale 'creamy' clots present in the heart chambers and there were multifocal haemorrhages present on the myocardium. Feeding of bovine colostrum was identified as a risk factor on the farm for these particular lambs and is consistent with the clinical signs and post-mortem findings described.



**Figure 14: Multifocal myocardial haemorrhages and pale lungs in a lamb with haemolytic anaemia. Photo: Shane McGettrick.**